

Ultrasonographic study of the plantar region of the hindlimb in a pure breed Catalan donkey

Pere Miquel Parés-Casanova* and Laura Junquera-Muñoz

Universitat de Lleida, Departament de Ciència Animal, ETSEA, 25198 Lleidaq, Catalonia, Spain

*Corresponding author: peremiquel@ca.udl.cat

Abstract

Parés-Casanova, P. M. & Junquera-Muñoz, L. (2021) Ultrasonographic study of the plantar region of the hindlimb in a pure breed Catalan donkey. *Bulg. J. Agric. Sci.*, 27 (3), 604–607

Although some studies of morphometric measurements by ultrasound in asses have been reported, few surveys of the measurements and proportions of plantar flexor tendons in the metatarsal region of donkeys are available in the literature. Topographic anatomy of the tendons and ligaments in healthy cases provides a normal atlas to diagnose abnormalities. The aim of this study was to provide the normal anatomy (thickness) of the digital flexors using diagnostic ultrasound and in standing the position in a pure Catalan breed. For this goal we obtained echographic planto-dorsal views of 8 adult animals belonging to this breed and thickness of superficial and deep tendons and distal accessory ligament (“check ligament”) on 3 levels on the metapode. Plantar tendons were divided into three levels from proximal to distal metatarsus. There appeared no differences between levels. Values for these tendons are reported. Deep tendon was the stronger, while superficial tendon was comparatively weaker. Our findings should be considered for clinical evaluation of this donkey breed.

Key words: echography; *Equus asinus*; ligaments; *Raça Asinina Catalana*; tendon anatomy

Introduction

There are no muscles in the equine digit, instead there are the tendons of insertion of the two extensor muscles and the two flexor muscles of the digit, a superficial and a deep. The deep tendon is enforced by an accessory ligament. The tendon structures located on the plantar area of the equids are (International Committee on Veterinary Gross Anatomical Nomenclature 2017):

- tendons of the digital flexor muscles: superficial (*flexor digitorum [digitalis] superficialis*), deep (*flexor digitorum [digitalis] profundus*) tendons
- distal accessory ligament (*lig. accessorium*, clinically known as “check ligament” or “inferior check ligament”)
- interosseous tendon (*mm. interossei*, clinically known as “suspensory ligament”).

Ultrasound is a safe, easy, non-invasive and effective technique for analysis of soft tissue injuries and currently accessible to any veterinarian clinician (Martínez, 2005) (Padaliya et al., 2015) My Lab FIVE. The incidence of fetlock joint and tendon disorders among other affections causing lameness in this species is rather unknown (Salem et al. 2019) computed tomography (CT). At the same time some studies have proved the correctness of the ultrasonographic inspections of the tendons and ligaments by comparing them with necropsy findings (Vosugh et al., 2017) 2, 3, 4, 5, 6. Therefore, comprehensive values of the digital flexors ultrasonographic images are required to describe accurately their anatomy. The ultrasound assessment of tendon anatomy focused on the study of echogenicity and size has been done in many horse breeds, such as Andalusian (Martínez, 2005), Arabian (Çelimli et al., 2010) (Vosugh et al., 2017) 2, 3, 4, 5, 6, Indian breeds (Padaliya et al. 2015) My Lab FIVE, Pyre-

nean Catalan Horse (Parés-Casanova et al. 2020), Mangalarga (Aristizábal et al. 2005) and Thoroughbreds (Çelimli et al., 2010), but few on asinines (Mostafa and Abd-Glil, 2008) (Nazem et al., 2015) (Abdulrazaq and Afshar, 2018) (Salem et al., 2019) computed tomography (CT).

The objective of our study is to determine the sectional measurements (“thickness”) of the flexor tendons in the metatarsal area in a donkey pure breed and determine if the cutting area has any effect over measurements.

The Catalan donkey (“Guarà Català”) is a breed from Catalonia, in north-eastern Spain and south-western France (Jordana and Folch 1996). It is a large breed, and generally weighs between 350–450 kilograms, jacks averaging 142 centimetres in height, and jennies 136 centimetres (Porter, 2016) (Jordana and Folch 1996). At the end of 2013, the total population in Spain was recorded as 851. The “Ministerio de Agricultura, Alimentación y Medio Ambiente”, the Spanish ministry of agriculture, lists the breed as “in danger of extinction”.

Materials and Methods

We studied adult 8 animals (1 male and 7 females, age range 4-7 years) belonging to Catalan Ass breed (Figure 1). Subjective assessment of clinical signs, visual and palpable abnormalities of flexor tendons was done. The equipment was set on the musculoskeletal scanning frequency pre-programmed according to the probe attached. No animal did present locomotory dysfunction or injuries related to the skeletal muscle system. All animals included in this work were officially registered as pure breed in the stud-book.



Fig. 1. A jackass belonging to Catalan Ass breed (photo: PMPC)

Animals included in the study were restrained with the help of owner in standing the position in the original stables of the animals, in stand-up position and subjected to physical restriction, and not being necessary the use of sedation under any circumstances. As this investigation was performed under field conditions, the body status of animal was not the same.

We apply the contact acoustic gel on the surface of the skin of the area to be inspected and on the surface of the probe to be in contact with the skin, in order to avoid the interposition of air between probe and skin. Ultrasonographic (US) device was equipped with a sectorial type probe which had a pad adapted at 5 MHz. Transverse images were obtained and thickness was measured. To obtain them we rotated the probe 90° until it was perpendicular to the transversal axis of the limb. We move the transducer around the area trying not to press too much anatomical structures to avoid possible artifacts and images digitally recorded. Measurements were performed on three levels determined by dividing the plantar metatarsal region into three equal zones, starting from the proximal border of the metatarsal bone (level 1), medium border (level 2) and proximal border of the proximal sesamoid bones (level 3). Therefore, structures of donkeys with different metatarsal lengths were measured at an equal ratio. Only left hindlimbs were echographed. Images were stored and ulteriorly measured with Digimizer freeware (available at <http://digimizer.findmysoft.com/>).

Statistical analysis

As data was normally distributed, ANOVA tests were used. Data were statistically analysed with software program PAST v. 2.17c (Hammer, Harper, and Ryan 2001). Significance levels at $p < 0.05$ were considered significant.

Ethical approval

All clinical cases in this research were examined and diagnosed as per standard examination and diagnostic procedure without harming or discomforts to animals.

Results

Ultrasonography is an imaging modality that can be used anywhere and allows rapid, noninvasive differentiation of soft tissue structures of the equine musculoskeletal system. Ultrasonography of the tendons and ligaments in the metapodial region is one of the easiest methods to study the cross-sectional diameters of the tendons. The tendons and ligaments of the metatarsal region of some pure breed donkeys were evaluated with that technique and all parts of the plantar structures were seen on the obtained pictures: skin,

Table 1. Morphometric measurements (thickness) for the flexor tendons and accessory ligament of the deep tendon for 8 ultrasonographed hindlimbs at metapodial level from Catalan Donkey breed. Measurement in mm, except for coefficient of variation, in %. Thickness expressed as planto-dorsal thickness

	Superficial flexor Tendon	Deep flexor tendon	Accessory ligament of the deep flexor tendon
Minimal value	2.4	2.8	2.5
Maximal value	5.2	6.5	8.5
Mean	3.6	4.5	5.8
Standard deviation	0.85	1.04	1.52
Coefficient of variation	3.63	4.26	5.77

subcutaneous tissues, superficial digital flexor tendon, deep digital flexor tendon, distal accessory ligament and interosseous tendon. The surface of the third metatarsal bone was clearly detected as a hyperechoic line. Wide synovial sheaths between tendons with high echogenicity were seen. Tendons presented homogenous echogenicities.

No ultrasonographic abnormalities were found. ANOVA test reflected no differences between levels for no structure, so for ulterior analysis data were clustered only according to each tendon. Table 1 reflect main descriptive

statistics for each tendon. Deep tendon, which serves more of a positional and supportive role for the foot, was the stronger, while superficial tendon, which has most of the spring-like function, was comparatively weaker (Figure 2). Values for each structure appeared statistically different and clearly below those described for horses, such as Arabians and Thoroughbreds (Çelimli, Seyrek-Intas, and Kaya 2010). The findings of our study are also highly compatible with the idea of the donkey being a less “dynamic” species than horses.

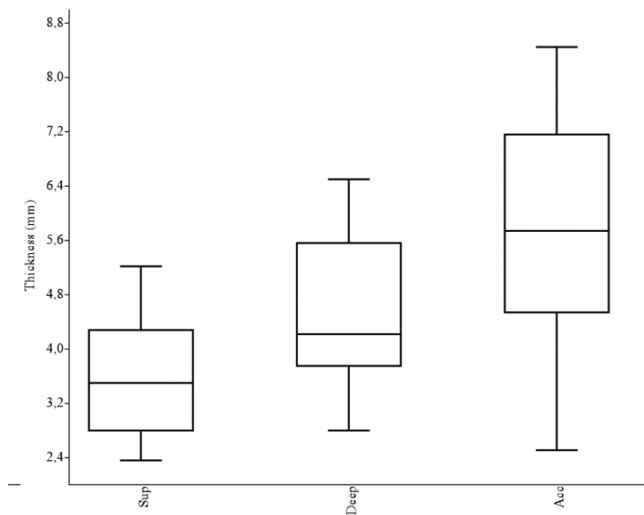


Fig. 2. Box plot for superficial tendon (“Sup”), deep tendon (“Deep”) and accessory ligament (“Acc”) for their thickness (n=8). For each tendon, the 25-75 percent quartiles are drawn. The median is shown with a horizontal line inside the box. The minimal and maximal values are shown with short horizontal lines (“whiskers”), drawn from the top of the box up to the largest data point less than 1.5 times the box height from the box (the “upper inner fence”). Distal accessory ligament was significantly the stronger, while superficial tendon was comparatively weaker

Discussion

Ultrasound is a widely used technique to evaluate tendon lesions on equids (Amin et al., 2014). The most commonly used ultrasound criteria for examining tendon and ligament injuries are the size (area) and echogenicity of tendons. However, in order to apply them in the equine clinic, they must first know their normal values. In this regard, several studies have been conducted on different breeds of horses, but although some studies of morphometric measurements by ultrasound in asses have been reported, no survey of the measurements and proportions of all flexor tendons and ligaments in the metatarsal region of Catalan donkeys was available in the literature.

Our finding could be attributed to the biomechanical and/or functional differences between donkeys and horses. These differences should be considered for clinical evaluation.

Conclusions

The objectives of this study were to describe for the first time the thickness of the tendons the metatarsus in a pure donkey breed from Catalonia (Spain).

Deep accessory ligament was the stronger, while superficial tendon was comparatively weaker.

Superficial tendon, deep tendon and distal accessory ligament presents a thickness average of 2.5, 8.5 and 5.8 mm respectively.

Authors' Contributions

- (a) Conception and design: Pere M. Parés-Casanova
- (b) Acquisition of data: Laura Junquera
- (c) Analysis and interpretation of data: Pere M. Parés-Casanova and Laura Junquera
- (d) Drafting the article: Pere M. Parés-Casanova and Laura Junquera
- (e) Revising article for intellectual content: Pere M. Parés-Casanova
- (f) Final approval of the completed article: Pere M. Parés-Casanova and Laura Junquera

Acknowledgments

The authors are thankful to owners of animals for their support and cooperation in carrying out study.

Competing Interests

The authors declare that they have no competing interests.

References

- Abdulrazaq, A.W. & Afshar, F.S.** (2018). Effects the pulsed electromagnetic field on the superficial digital flexor tendonitis in donkey: Sonography study. *Basrah Journal of Veterinary Research*, 17(3), 472–90.
- Amin, M., Elbakary, R., Alsafy, M. & Fathi, N.** (2014). Radiographic and computed tomographic anatomy of the fetlock, pastern and coffin joints of the manus of the donkey (*Equus asinus*). *Alexandria Journal of Veterinary Sciences*, 41(1), 68.
- Aristizábal, F. A. M., Souza, M. V., Aranzales, J. R.M. & Ribeiro, J. I.** (2005). Valores biométricos obtidos por ultrasonografia dos tendões flexores e ligamentos acessório inferior e suspensório da Região Metacárpica Palmar de Cavalos Mangalarga Marchador. *Arquivo Brasileiro de Medicina Veterinária e Zootecnia*, 57(2), 156–62.
- Çelimli, N., Seyrek-Intas, D. & Kaya, M.** (2010). Morphometric measurements of flexor tendons and ligaments in Arabian Horses by ultrasonographic examination and comparison with other breeds. *Equine Veterinary Education*, 16(2), 81–85.
- Hammer, Ø., Harper, D.A.T. & Ryan, P.D.** (2001). PAST v. 2.17c. *Palaeontologia Electronica*, 4(1), 1–229.
- International Committee on Veterinary Gross Anatomical Nomenclature** (2017). World Association of Veterinary Anatomist. *Nomina Anatomica Veterinaria*.
- Jordana, J., & Folch, P.** (1996). The endangered Catalan Donkey breed: The main ancestor of the American ass or mammoth. *Journal of Equine Veterinary Science*, 16(10), 436–441.
- Martínez, M. de los Llanos** (2005). Estudio Ecográfico (Ecogenicidad y Área) de Los Tendones Flexores de La Extremidad Anterior Del Caballo Pura Raza Español. Universidad de Murcia. <http://nadir.uc3m.es/alejandro/phd/thesisFinal.pdf>
- Mostafa, M.B. & Abd-Ghli, A.I.** (2008). Radiographic and Ultrasonographic Findings of Some Fetlock Disorders in Donkeys. *Iranian Journal of Veterinary Surgery*, 3 (4)(9), 49–56.
- Nazem, M. N., Sajjadian, S. M., Vosough, D. & Mirzaesmaeili, A.** (2015). Topographic Description of Metacarpal Tendons and Ligaments of Anatoly Donkey by Ultrasonography and Introducing a New Ligament. *Anatomical Sciences*, 12(4), 153–60.
- Padaliya, N.R., Ranpariya, J.J., Kumar, D., Javia, C.B., Barvalia, D.R.** (2015). Ultrasonographic assessment of the Equine Palmar Tendons. *Veterinary World*, 8(2), 208–812.
- Parés-Casanova, P.M., Salamanca-Carreño, A., Bermúdez de Gracia, E., Boudra, A. & Crosby, R.A.** (2020). Estudio ultrasonográfico de la Región Metapodial en Potros de la Raza “Cavall Pirinenc Català. *Actas Iberoamericanas de Conservación Animal*, 14(2019), 4–7.
- Porter, V.** (2016). Asses. In: *Mason's world dictionary of livestock breeds, types and varieties*, ed. V. Porter, G.L.H. Alderson, S.J.G. Hall and D.P. Sponenb, Cambridge University Press, 1–53. https://cab.presswarehouse.com/sites/stylus/resrcs/chapters/1845934660_1stChap.pdf.
- Salem, M., El-Shafaeya, E.-S., Esam, M. & Zaghoul, A.** (2019). Ultrasonographic, computed tomographic, and magnetic resonance imaging of the normal donkeys (*Equus asinus*) digit. *Journal of Equine Veterinary Science*, 74, 68–83.
- Vosough, D., Nazem, M.N. & Lahuti, S.** (2017). Anatomy and ultrasonographic morphometric measurements of Palmar Metacarpal Tendons and Liga-Ments in Pure Persian Arabian Horses. *Anatomical Sciences*, 14(4), 153–62.

Received: July, 15, 2020; Accepted: October, 1, 2020; Published: June, 2021